

Ontogenetic changes in the skull of the European wildcat (*Felis silvestris* SCHREBER, 1777)

CLARA STEFEN¹ & DIETRICH HEIDECHE†²

¹ Senckenberg Naturhistorische Sammlungen Dresden, Museum für Tierkunde, Königsbrücker Landstraße 159
clara.stefen(at)senckenberg.de

² Institut für Zoologie der Martin Luther Universität Halle-Wittenberg, Zoologische Sammlungen, Domplatz 4, 06099 Halle/Saale

Accepted on January 20, 2012.

Published online at www.vertebrate-zoology.de on July 06, 2012.

> Abstract

The postnatal changes of the skull of the male and the female European wildcat are described in detail using linear measurements and geometric morphometrics. Overall, the analysis of the linear measurements and of the geometric morphometrics of the landmark data indicate the same postnatal changes in the skull morphology, which are, however, described better by geometric morphometrics. The changes mainly affect the caudal part of the skull and, in the mandible, the coronoid and the angular process as well as the ventral rim. Three growth phases can be distinguished particularly on the basis of the linear measurements with the fastest growth and the most obvious changes in the skull occurring from birth to about 7 months, slowed down growth from about 7 to 14 months, and only little growth from 14 to about 24 months of age, when the growth curves for most linear measurements level off. None of the easy and non-destructive means of the linear measurements employed was found to clearly determine the age of a skull.

> Zusammenfassung

Die postnatalen Veränderungen des Schädels von weiblichen und männlichen Europäischen Wildkatzen werden anhand von linearen Messungen und mit Hilfe der Geometrischen Morphometrie im Detail beschrieben. Insgesamt lassen sich die postnatalen Veränderungen des Schädels mit beiden Methoden darstellen, doch werden sie mit der Geometrischen Morphometrie besser illustriert. Drei Wachstumsphasen werden anhand der linearen Maße deutlich unterschieden: 1. Von Geburt bis etwa 7 Monate mit dem schnellsten Wachstum und den deutlichsten Veränderungen der Form des Schädels. 2. Von etwa 7 bis 14 Monaten mit langsamerem Wachstum. 3. Von 14 bis etwa 24 Monaten mit nur geringem Wachstum; die adulten Werte sind für die meisten Parameter erreicht. Im Schädel betreffen Veränderungen vor allem den caudalen Bereich, in der Mandibel den Coronoid und Angular Fortsatz sowie den ventralen Rand. Keine der genutzten linearen Messstrecken eignete sich als einfache Methode zur individuellen Altersbestimmung des Schädels.

> Key words

Postnatal changes, geometric morphometrics.

Introduction

The outer and cranial morphology of the European wildcat (*Felis silvestris* SCHREBER, 1777) has been dealt with for centuries (e.g. summarized by PIECHOCKI, 1990; STEFEN & GÖRNER, 2009). One of the major concerns has often been the differentiation of wild and domestic cats (e.g. SCHAUENBERG, 1969, 1977; KRATOCHVÍL & KRATOCHVÍL, 1970; DANIELS *et al.*,

1998; BEAUMONT *et al.*, 2001; REIG *et al.*, 2001). The variability within populations has been less focussed on (e.g. KRATOCHVÍL, 1973; SLÁDEK *et al.*, 1971, 1972; STEFEN & HEIDECHE, 2011). Ontogenetic changes in the skull morphology of wild and domestic cats have, in particular, been indicated by KRATOCHVÍL (1973) and KRÜGER *et al.* (2009). So far, no direct correlations be-

tween the morphological changes and the age of an individual specimen have been documented in detail for wildcats.

The aim of this study was to describe in more detail the postnatal changes in the skull morphology of wildcats by considering the age of both sexes and, furthermore, to see which areas of the skull change the most, how fast these changes occur, and whether they differ between the sexes. Classical linear measurements and correlations to age were used as well as the methods of geometric morphometrics as the latter permit a good quantification and visualization of shape change (DRAKE & KLINGENBRG, 2008). One aspect of studying the linear measurements was to find a non-destructive and easy-to-use tool to determine the unknown age of wildcats in museum and institute collections. Skull development will be discussed in relation to life history events.

Materials and methods

Materials

The 67 wildcats, 40 males (m) and 27 females (f), in the collection of the Zoological Institute of the Martin-Luther-Universität Halle-Wittenberg in Halle were used in this study. Furthermore, several cats from other collections were included: 5 (3 f, 2 m) from the Senckenberg Forschungsinstitut and Naturmuseum Frankfurt and 3 from the Museum für Naturkunde Berlin. The specimens ranged from 3 to 78 months in age (Fig. 1). All specimens originated from the Harz region or from Thuringia.

The wildcats were distinguished from domestic cats by cranial volume, cranial index, and, when available, the intestine length learned from the museums' records. According to PIECHOCKI (1990), the cranial volume of wildcats ranges from 32.5–50 cm³ and for domestic cats from 20–35 cm³, hence, a cranial volume of > 35 cm³ can be used to identify wildcats. For cats with a cranial volume of 32–35 cm³ the cranial index (= greatest total skull length : cranial volume) must be calculated to clearly identify the type of cat. SCHAUBENBERG (1969) used the cranial index to differentiate wild and domestic cats: a cranial index of < 2.75 is indicative of wildcats whereas one of > 2.75 is indicative of domestic cats (for skulls with fully developed adult dentition). In cases where neither the cranial volume nor the intestine length were available,

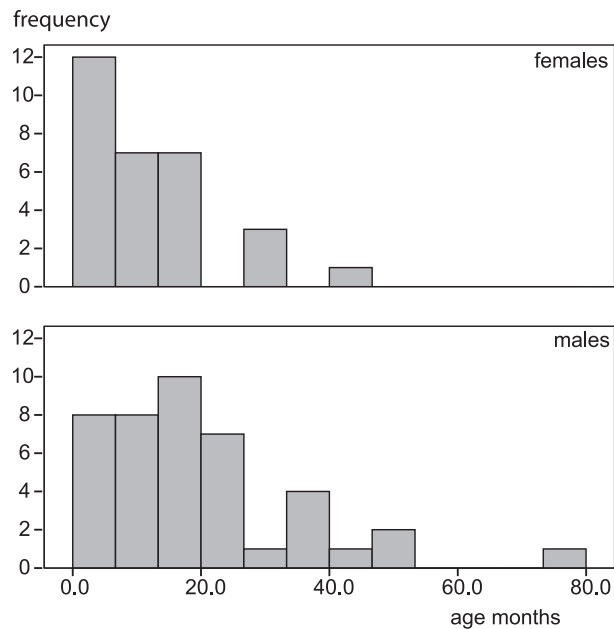


Fig. 1. Frequency of the known age of the studied individuals separated according to sex.

a combination of the glabella, the location of the palatine foramen, the nasal length, and the angular process were used for the determination.

Prior to the present study the determination of the individual age had been performed by counting the cement layers at the roots of the maxillary canines (PIECHOCKI & STIEFEL, 1988). The age of the specimens were taken from this publication.

For the geometric morphometric analysis, photographs were taken of the skulls and mandibles from the collection in Halle by placing them on a cushion to have the respective aspect of interest parallel to the camera. The sample that could be used consisted of 37 mandibles (m 23, f 14), 39 skulls in the dorsal view (m 23, f 16), 42 skulls in the ventral view (m 26, f 16) and 44 skulls in the lateral view (m 30, f 14). As far as possible, all the individual specimens were photographed from the same side. In a few cases, mirror images of the other side had to be used for the digitization of the landmarks.

Methods

Linear measurements were taken in partial accordance with FRENCH *et al.* (1988), KRATOCHVIL (1973), and YAMAGUCHI *et al.* (2004). The measurements are listed in Table 1 and illustrated in Figure 2. These data were used in Pearson correlation analyses against age performed with SPSS 16.

For the geometric morphometric analyses, 18 landmarks (LM) were chosen on the dorsal and the ventral aspect of the skull and the lateral view of the mandible and 20 on the lateral aspect of the skull as illustrated in Figure 3 and listed in Table 2. Overall landmarks were chosen to cover the entire structure of the skull and the mandible. However, concerning the mandible, the coronoid, the condyle, and the angular process as well as the course of the mandible joining them were focused on as relations between them are assumed to be particularly important for making the distinction between wild and domestic cats. The aim was to look for easily identifiable landmarks in each specimen. For this, junctions of sutures in the skull, extreme points, and maximum or minimal curvatures were selected as landmarks.

The digitalization of the landmarks was carried out using the TPSdig2 software (SUNY Stony Brook, <http://life.bio.sunysb.edu/morph/index.html>). These coordinate data were imported into the MorphoJ program (KLINGENBERG, 2010; http://www.flywings.org.uk/MorphoJ_page.htm). This program was then used for all further shape analyses. First, the Procrustes superimposition was used to rescale the landmark configurations to a standard size, position, and orientation. In this way the centroid size of the landmark configuration was computed as the square root of the sum of the squared distances of all the landmarks from their centroid. For the analysis of the changes during the ontogeny, multivariate regressions of the Procrustes coordinates were performed on the respective variables. To test for digitalization errors, the landmarks on six mandibles were digitized four times with none of them indicating digitization errors.

Results

Linear measurements

The postnatal changes of male wildcats are illustrated by several photographs (Fig. 4, 5) as well as in scatter diagrams for some of the cranial parameters (Fig. 6). The Pearson Correlations between the cranial variables and the individual age show a clear correlation of most variables and age, with most of them increasing, but with *dtemp* decreasing. A marked sexual dimorphism can also be seen, with the males showing more correlations to age and a stronger statistical significance, than the females (Table 3). Only for the follow-

ing variables could no statistically significant correlation to age be observed in either sex: *bn*, *afor*, *schind*, and for the tooth measurements *LP4*, *BP4*, *CH*, *Cl*, *pml*, *lp3*, *lp4*, *lm1*, *cl*, and *ch*.

From the scatter diagrams of the variables opposite age it can be derived that the increase in size for nearly all the variables with growth takes place the fastest during the first few months. The curves indicate three basic growth phases: the fastest growth from birth to about 7 months, slowed down growth from about 7 to about 14 months, and only little growth from 14 months to about 24 months of age, when the curves level off. Particularly *ZW*, *ZwM1*, *bCa*, *mandl_1*, *mandl_2*, *corh*, and *y17* continue to grow with even a slight increase in *CranV*.

For a few variables the lowest level of the approximate adult size range is reached at about 7 months: *cond*, *bullh*, which is, however, very variable, and *shbull*.

Shape

The overall shape of the skull changes markedly particularly within the first 5–7 months. The skull of juveniles, particularly newborns, but also of up to about three-month-old wildcats, is well rounded and oval in shape (including the zygomatic arches) in the dorsal view (Fig. 4). It appears compact and well inflated in the lateral view (Fig. 5). With growth, the skull elongates, particularly in the caudal cranial region, the orbits appear to tilt more, and the frontal flattens whereas the anteriodorsal naso-frontal-maxillary region becomes a bit rounder.

In the dorsal view of grown wildcats the overall shape is more complex than in newborns, the cranium appears rounded whereas the frontal with the postorbital processes, the nasals, and the developing sagittal crest at the corners forms a squared rhombic roof. The zygomatic arches extend far, laterally encasing the large orbitae and the temporal fossae. Whereas in very young skulls the largest zygomatic width is at the orbita, it is at the distal part of the zygomatic arc at the part that encloses the temporal fossa in skulls from about 6 months of age.

The development of the nuchal and the sagittal crests starts in male wildcats at about 6–10 months of age (Fig. 3), and the temporal ridges are developed at about 5 to 6 months. The temporal fossa increases markedly in size from birth to about 6 months of age and continues to increase as the zygomatic width continues to widen, yet more slowly.

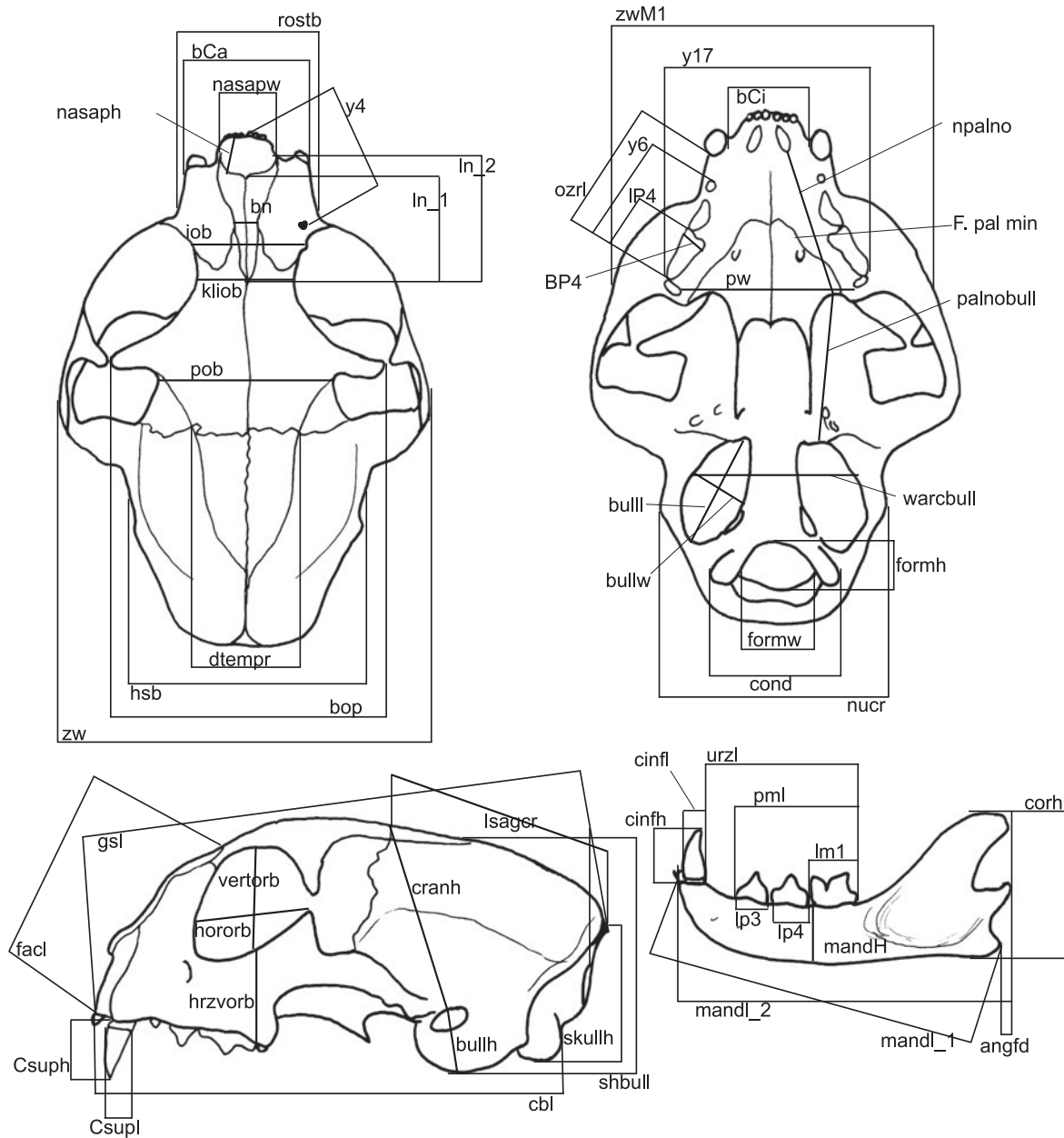


Fig. 2. Schematic illustration of linear measurements taken as explained in table 1.

Geometric morphometrics

The sexual dimorphism was clearly supported by the results of discriminant analyses with the Procrustes superimposition of the landmark data for all the views of the skull and the mandible.

The dorsal aspect of the skull (Fig. 7A) shows that most of the postnatal shape changes occur in the caudal part of the skull, including the development of the nuchal and the sagittal crest, the change of the relative position of the fronto-parietal sutures (LM 3), the broadening of the skull at the postorbital process and in the zygomatic width, and a few changes in the facial part of the skull, particularly in the elongation of

the nasals. The distal end of the nasals, the maxilla-frontal-nasal meeting, and the anterior orbital rim stay in place relative to each other, but the distance of the orbits to the nasals increases slightly. In the ventral view (Fig. 7B) the shape changes are more the same all over the skull but smaller in the anterior-most region. They include the widening of the skull at the zygomatic arch, the relative movement of the choana towards the anterior and thus the relative shortening of the palate. As LM 10 and LM 11 move towards each other with age, a decrease in the height of the foramen magnum could be assumed since formh is very variable and shows a correlation to age only in males. Postnatal changes are also apparent in the lateral view of the skull (Fig. 76C) and affect the caudal part of the

Table 1. List of abbreviations and explanation of measurements taken.

gsl	greatest skull length, from inion (point where the two superior nuchal crest meet in sagittal plane) to prosthion (maxillary bone at alveoles of incisors in sagittal plane), nearest way
cbl	condylobasal length (condylion, furthest extension of condyles to inion)
zw	zygomatic width, maximum
zwM1	zygomatic width at M1, measured from ventral
nucr	maximum width across nuchal crest
hsb	maximum cranial width (maximum across squamosum)
dtemp	distance between frontoparietal ridges at their intersection with frontoparietal sutures
iob	interorbital width measured between grooves of angularis oculi veins
bn	width of nasal bones at premaxilla/maxilla/nasal sutures
nasapw	maximum internal width of nasal aperture
nasaph	maximum internal height of nasal aperture (might be oblique)
cranh	cranial height from porion (dorsal most point of auditory meatus) to bergma (intersection of frontoparietal sutures at sagittal plane)
lsagr	potential length of sagittal crest, from intersection of frontoparietal sutures to inion
bop	width across orbital processes
pob	width across postorbital constriction
skullh	skull height from condyles to inion
ln_1	length of nasal bones at midline
ln_2	maximal length of nasal bones
facd	facial length, from prosthion to nasion (caudal end of nasals)
vertorb	maximal vertical diameter of orbit
hororb	horizontal diameter across orbit
hzvorb	vertical distance from orbital to maxillary bone between P4 and M1
bCa	width of maxillary bone at canines
bCi	distance between canines
rostb	rostral breadth, maximal width of snout
pw	palate width measured between M1 (tips of callipers tugged in between palate and M1 from distal in ventral view)
acbull	width across bullae from porion to porion
formw	maximal width of foramen magnum
formh	height of foramen magnum (occasionally occurring high notches of the foramen are not included in the measurement)
cond	maximal width across occipital condyles
npalno	distance from internal nares to anterior palatal notch
palnobull	distance from anterior palatal notch to depression of the tympanic bulla at base of styloid process
bulll	length of tympanic bulla
bullw	width of tympanic bulla
bullh	height of tympanic bulla, from top of auditory meatus to maximal ventral extension of bulla
ozrl	length of maxillary tooth row from distal of canine to distal end of P4
IP4	length of P4 crown
bP4	width of P4 crown
Ch	height of crown of maxillar caninus from alveole to tip
Cl	length of crown of maxillar caninus
afor	distance between foramen lacerum and foramen ovale
shbull	height of skull measured vertically above bullae tympanica
cranV	cranium volume, measured to the nearest 0.5 cm ³ using glass beads of 1 mm diameter
mandls	length of mandible measured from the alveoles of the incisors at sagittal plane (pogonion) to the caudal end of angular process
mandl	length of mandible measured from pogonion to condyle parallel to ventral rim of mandible
corh	height of mandibular ramus at coronoid process
angfd	from angular process to an imaginary line extended from condyle and coronoid process; positive values indicate an angular process not extending as far caudally as this line, negative values indicate coronoid process extending not as far caudally as angular process
mand	height of mandibular ramus between p4 and m1
uzrl	length of mandibular tooth row from distal end of caninus to distal end of m1
pm1	length of p-m1 (at alveoles)
lp3	length of p3 at alveole
lp4	length of p4 at alveole
lm1	length of crown of m1 (measured from above)
cl	length of mandibular caninus
ch	height of mandibular caninus from alveole to tip
y4	distance from prosthion to middle of infraorbital foramen
y17	greatest width across both P4
y6	length of tooth row from P2-P4
kliob	interorbital breadth measured at shortest distance between orbits

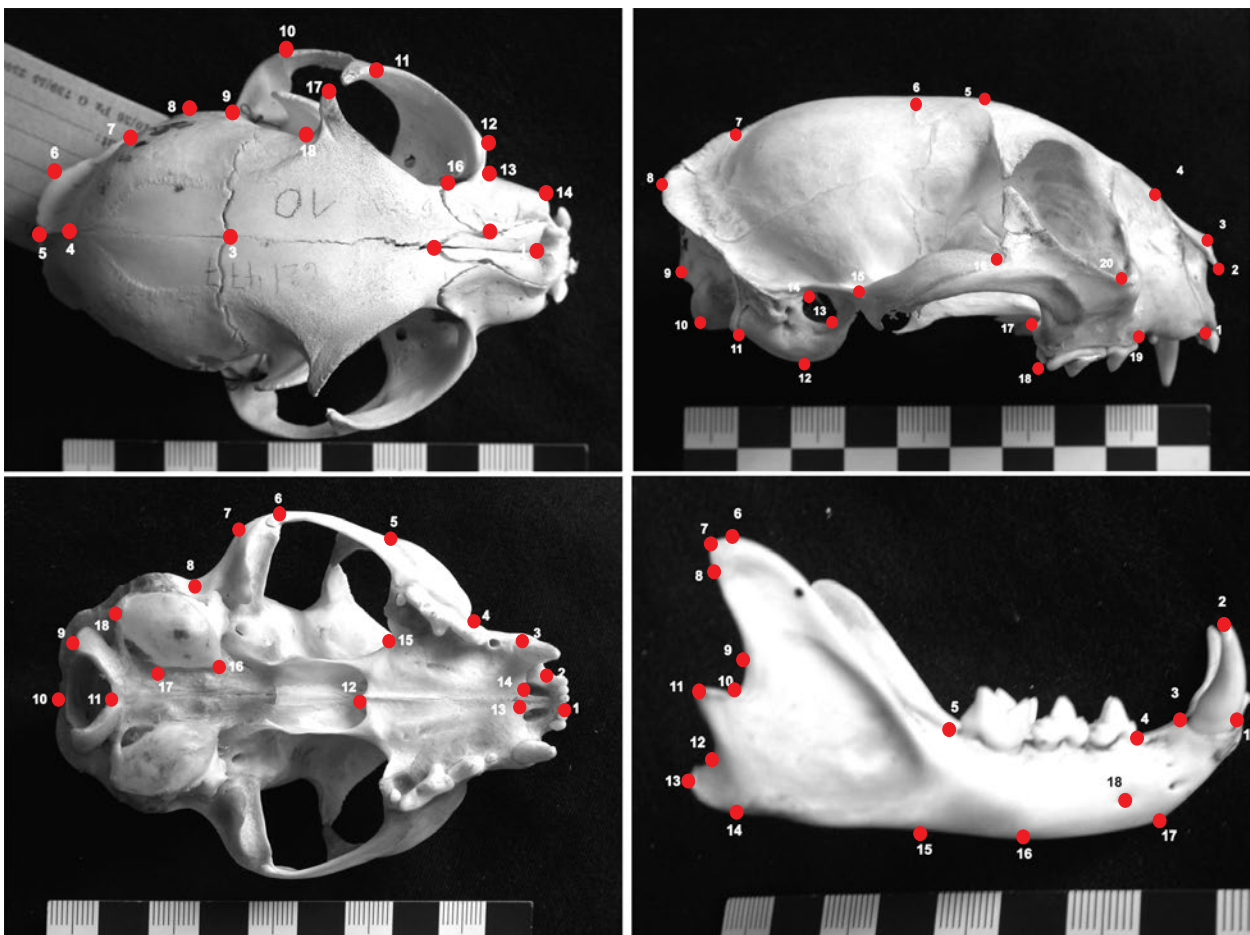


Fig. 3. Schematic illustration of the landmarks used in dorsal, ventral and lateral view of the skull as well as on lateral side of the mandible. Explanations of landmarks in table 2.

skull more than the anterior part. The changes associated with the development of the nuchal and the sagittal crest as well as the overall flattening of the roof of the skull (LM 5, 6) are prominent. The elongation of the zygomatic arch and the cranium (LM 11–16) and some changes associated with the dental arch (LM 18, 19, 1) are also indicated.

The shape changes of the mandible (Fig. 7D) include nearly all the landmarks but differ in direction and magnitude. The coronoid process increases in height, the angular process in length, and the condyle shifts slightly towards the posterior. The ascending ramus of the mandible also broadens (LM 5, 11).

Discussion

The changes in the shape and the size of the skull of wildcats, from neonate to older age, were indicated particularly in the dorsal view by KRATOCHVÍL (1973),

KRÜGER *et al.* (2009), and GARCÍA-PEREA *et al.* (1996). They are documented here in more detail (Fig. 4, 5) as well as being discussed in relation to life history events. The postnatal changes in the expression, the form, and the course of the temporal ridges and the sagittal crest, including the development of a lyrate form as well as the development of a nuchal crest are e.g. also known from lynxes (GARCÍA-PEREA, 1996), whose development is very similar to that of wildcats. They are further known also from other mammals such as beavers (HINZE, 1950), where the postnatal changes of the temporal ridges and the sagittal crest help determine the age of specimens (STEFEN, 2009).

The nearly constant values of the tooth measurements result from the fact that only permanent teeth were included in the analyses as their size does not change with age; only the height of the canines changes due to wear.

In the ventral view of the skull, the changes of the rim of the foramen magnum are indicated with geometric morphometrics (Fig. 7B), which is not supported in the correlations to age of the linear measurements of formh and formw (Tab. 3). It is therefore assumed that the apparent age-related decrease in size of the fo-

Table 2. List of landmarks chosen for geometric morphometric analysis.

landmarks on dorsal aspect of skull	
01	anterior point of midline between nasals
02	posterior most point of midline between nasals
03	meeting of frontoparietal sutures
04	anterior most end of sagittal crest if developed (otherwise identical to next landmark)
05	distal most point of midline of skull
06	prominent bulging of nuchal crest
07	end of nuchal crest
08	lateral most extension of skull
09	posterior end of zygomatic arch
10	laterodistal most extension of zygomatic arch
11	point anterior of orbital process of zygomatic arch
12	anteriolateral most extension of zygomatic arch
13	'depression' anterior to zygomatic arch
14	extension of alveole of Caninus
15	suture of maxillary, nasal and frontal bone
16	where maxillary intersects orbital rim
17	tip of orbital process
18	point of postorbital constriction

landmarks on ventral aspect of skull	
01	between first incisors in midline
02	at apparently 'deepest' point between incisor and canines
03	at posterior end of alveole of Caninus
04	at anterior onset of zygomatic arch
05	at slight depression of zygomatic arch
06	at lateral most extension of zygomatic arch
07	at postriolateral most extension of zygomatic arch
08	at postorbital constriction
09	at condyle of foramen magnum
10	distal most extension of foramen magnum in midline
11	anterior most extension of foramen magnum in midline
12	at anterior end of choane or posterior end of palatine bone in midline
13	premaxillary-maxillary suture in midline
14	caudal end of incisive foramen
15	anterior most notch of palate
16	anterior end of bulla
17	extension of bulla towards midline
18	caudal end of bulla

landmarks on lateral aspect of skull	
01	at anterior rim of alveole of incisor
02	at lateral tip of nasal
03	at midline of nasal bones
04	at distal most extension of nasals
05	at 'knickungspunkt' of skull (more or less in extension of rim of orbital process)
06	at parietal-frontal suture at midline
07	anteriormost end of sagittal crest if there is any
08	most distal point of skull
09	extension of occipital
10	condyle
11	distal point of bulla
12	ventral point of bulla
13	anterioventral point of external auditory meatus
14	dorsoposterior most point of external auditory meatus
15	extension of squamosal rim
16	jugal-maxillary suture at dorsal rim of zygomatic arch
17	dorsal rim of maxillary below zygomatic arch
18	posterior end of alveole of P4
19	greatest extension of curvature anterior to P3
20	anterioventral rim of orbita

landmarks on lateral side of mandible	
01	midline between incisors of both mandibles
02	tip of incisor
03	distal rim of alveole of incisor
04	anterior rim of alveole of premolar teeth (p3)
05	depression just distal of carnassial (m1)
06	most dorsally extended tip of coronoid process
07	most distally extended tip of coronoid process
08	border of visible „thickening“ of coronoid process
09	maximal anterior curvature of ramus between coronoid and condyle
10	anterior point of condyle
11	distal most point of condyle
12	maximal anterior curvature of ramus between condyle and angular process
13	distal most tip of angular process
14	ventral most curvature of angular process
15	ventral most curvature below anterior part of masseteric fossa
16	ventral rim below between p4 and m1
17	curvature below diastema, below point 4
18	position of distal most foramen mentale

ramen magnum reflects a slight shift in the angle of the occipital plane to the basiocranium. In the present study, this angle was not measured on the skulls.

Three periods of growth are suggested of which the first one, marked by very fast growth, is completed at about 7 months of age. A few variables seem to reach the lowest level of the approximate adult range at this age at which permanent dentition is completed (CONDÉ & SCHAUENBERG, 1978). From this age onwards there is no constraint on the mandible and the skull to increase in size in accordance with the teeth, or alveoles. The second period of growth lasts up to an age of about 14 months, which is shortly after sexual maturity has been reached – at about 12 months for females and

9–10 months for males (PIECHOCKI, 1990). The last period with the slowest growth lasts until the age of about 20–24 months. For domestic cats, fusion of the ossification centres of bones occurs between 14 and 20 months of age, with a possible delay of the upper limit (SMITH, 1969). For wildcats, SCHAUENBERG (1980) stated that “physical maturity, which is the stage reached when the process of ossification of the epiphyses is completed, arrives between 18 and 19 months.” The findings of the reduced growth of the skull with its growth apparently coming to an end at about two years of age which, in the present study, was observed for wildcats correspond well to Schauenberg's observations concerning domestic cats and wildcats. Only

Table 3. Statistical significance of Pearson correlation of linear cranial measurements to age separated according to age. Last column indicates approximate age, when variable reaches about adult size values.

variable	female	male	
	n = 38	n = 42	
	3–42 M	3–78 M	
gsl	**	**	~ 14
cbl	**	**	~ 14
zw	**	**	20
zwM1	*	**	14
nucr	**	**	14
hsb		*	
dtemp		**	
iob	*	**	14
bn			
nasapw	*	**	14
nasaph	*	*	
cranh	*	**	12
lsagcr	*	**	14
bop	*	**	14
pob			
skullh	*	**	14
ln_1		*	14?
ln_2	*	**	?
facd	*	**	15
vertorb	*	**	10
hororb	*	**	12
hzavorb	**		
bCa		**	~ 20
bCi	*	**	~ 14
rostb	**	**	~ 20
pw		**	~ 20
wacrull	*	**	~ 14
formw		*	~ 7
formh		*	~ 7
cond		*	~ 7
npalno		**	~ 14
palnobull	*	**	
bulll		**	~ 14
bullw	**	**	~ 14
bullh	*		~ 7 ?
ozrl		*	~ 12
IP4			
BP4			
Ch	**	*	
Cl			
afor			
shbull		**	~ 12
cranV		*	> 14
schind			~ 14
mandl_1	**	**	~ 12
mandl_2	**	**	~ 14
corh	**	**	~ 14
angfd	**	**	~
mandH	**	**	~ 14
uzrl	*	**	
pml		*	
lp3			
lp4			
lm1			
cl			

ch	female	male	
variable	n = 38	n = 42	
	3–42 M	3–78 M	
ratZw		*	
sagind			
nasvol	**	**	
bullvol	**	*	
mandsh	*	**	
orbar	*	**	
cheekb		*	
formagar		*	
y4	*	**	
y17		**	
y6		**	
kliob	**	**	

** significant on the level of 0.01

* significant on the level of 0.05

a few parameters of the wildcat skulls continue to change with age such as dtemp. GARCÍA-PEREA (1996) stated for *Lynx pardinus* and *L. lynx* that the distance between the temporal ridges stops decreasing at about two years of age. From the observations concerning *Felis silvestris* skulls it can be assumed that the nuchal and the sagittal crest continue to grow, however, respective measurements were not the aim, here.

The development of the nuchal and the sagittal crest starts in male wildcats at about 6–10 months of age (Fig. 3) while the temporal ridges develop at about 5–6 months. The temporal fossa increases markedly in size from birth to 6 months of age and continues to increase as the zygomatic width continues to widen.

The temporalis muscle, which, in carnivores, plays a major role in chewing, especially in the hyper-carnivorous felids, originates at the temporal ridges, the temporal fossa, and the sagittal crest, and therefore its mass is able to increase with the growth of the sagittal crest and the temporal fossa. Associated with this is the elongation of the coronoid process on which the temporalis muscle inserts. The temporal fossa becomes markedly enlarged in the first 5–6 months of age, and a sagittal crest starts to form. The increase of the zygomatic width and, to a lesser degree, of the zygomatic arch length as well as the lengthening of the angular process also indicate an increase in the masseter muscle fibres. From birth to about 5–6 months this development is the strongest although it continues with age. At about 5 months young cats start leaving their mother to begin leading an independent life (DE LEUW, 1976) while permanent dentition does not develop before about 7 months of age (CONDÉ & SCHAUBENBERG, 1978). Therefore, at 5 months the juve-

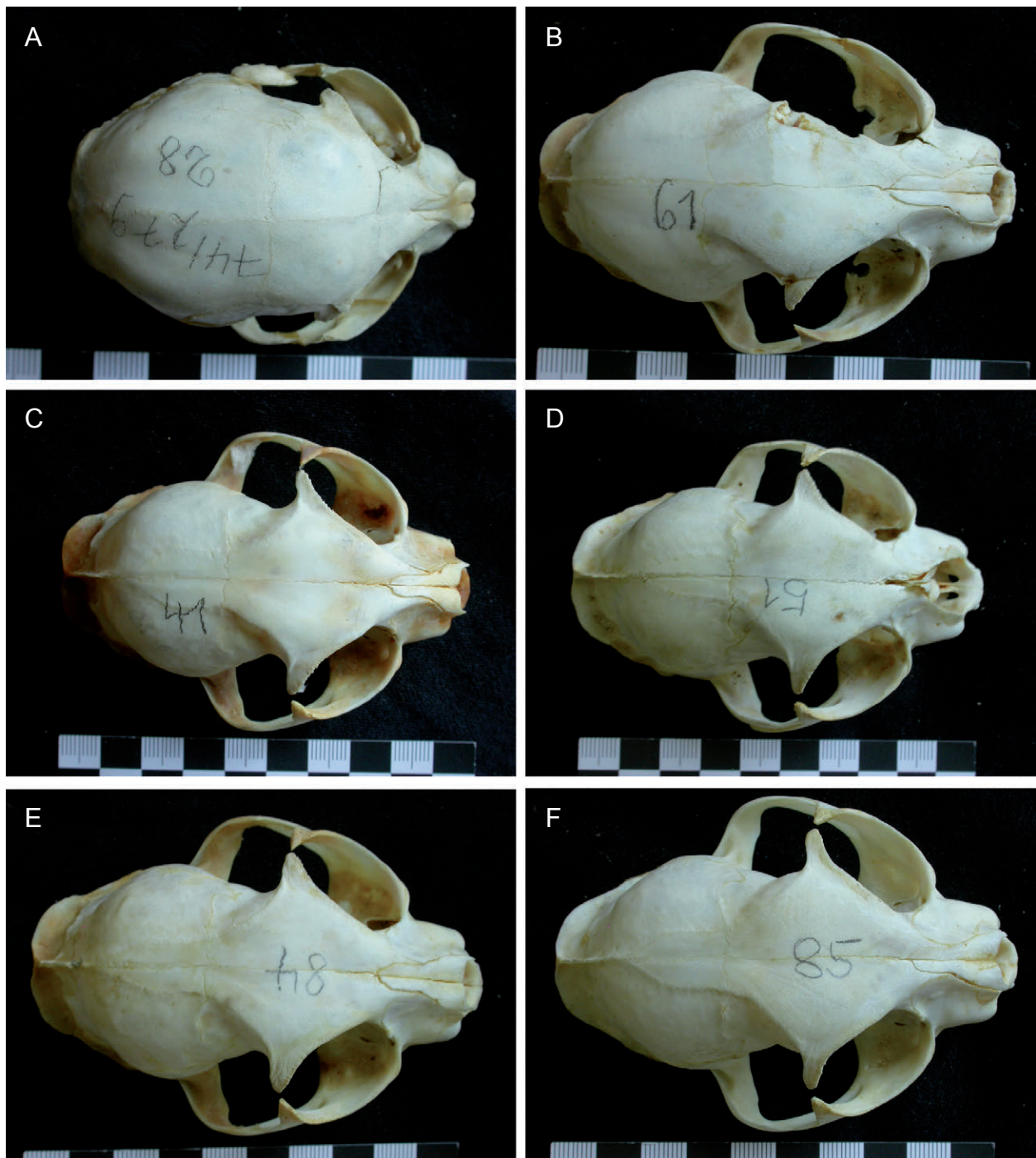


Fig. 4. Skulls of male wildcats in the collection of the University Halle-Wittenberg in dorsal view. A) 74/279, 3 months old, B) 81/100, 6 months, C) 79/37, 10 months, D) 79/235, 14 months, E) 85/167, 20 months and F) 85/168, 36 months old.

niles must look for vertebrate food on their own like adult cats, for which they need well developed chewing muscles. This requirement may be what produces the great changes and the intensive growth within the first few months of a cat's life. It can thus be assumed that the period between weaning from the mother and being able to use a well developed chewing musculature and permanent dentition is the most critical period for wildcats in terms of feeding. The changes in the skull's shape in the second period from about 7–14

months of age are not as rapid and, as Fig. 4 indicates, occur on a skull that already has the basic adult outline whereas especially the temporal ridges, the sagittal crest, and the zygomatic breadth continue to change.

The average developmental stages are shown here in a timeline and in relation to major life history events:

0 months	birth
5/6 months	weaning
7 months	permanent dentition in place

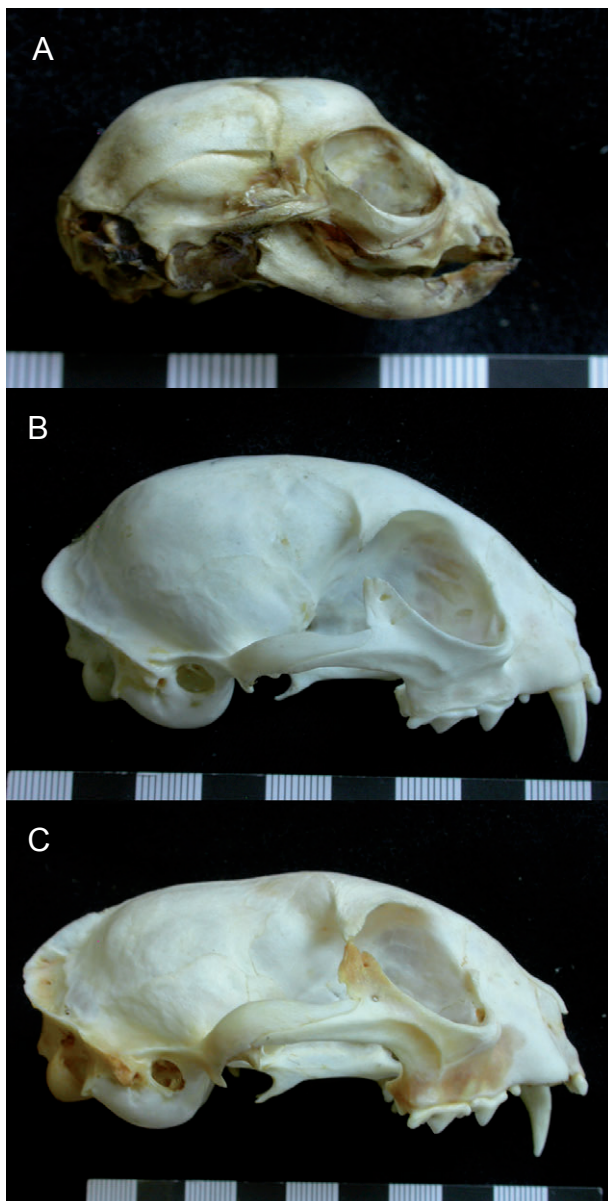


Fig. 5. Skulls of male wildcats in the collection of the University Halle-Wittenberg in lateral view. A) 87/125, first weeks, but not exactly aged, B) 86/47 7 months, can C) 86/25, 2 years old.

9 – 12 months reproductive maturity
20 months adult skull shape

In lynxes, the development of the sagittal crest begins at the end of the first year, when [the young] adopt an independent way of life (GARCÍA-PEREA, 1996). This is clearly later than in wildcats, but corresponds to the adoption of an independent life in a similar way and supports the importance of the temporalis muscle.

During the ontogeny, the in-levers as well as the out-levers of the masseter and the temporalis muscle increase with skull size. Whether there is a mechanical advantage to these two chewing muscles, and if, to what extent, cannot be clearly determined here

since the estimators on the mandible, as given by RADINSKI (1981), were not measured. It can however be deduced from Fig. 7C that the moment arm or in-lever of the superficial masseter (distance from the tip of the coronoid process to the condyle) and of one portion of the temporalis muscle (distance from the condyle to the ventral rim of the angular process, RADINSKI, 1981) increase but cannot be put in relation to the out-lever, the carnassial (distance from the mandibular condyle to the bite point). “Carnassial function in young lynxes is assumed by dp3 and dp4, but this function shifts to P4 and m1 in adults, the morphology of pP3 and dp4 being similar to that of P4 and m1” (TUMILSON & MACDANIEL, 1984). This shift occurs in other carnivores such as domestic cats (GAUNT, 1959) and *Felis silvestris* in a similar way (GARCÍA-PEREA *et al.*, 1996).

The sample size, the high overall variability – probably at all age stages – and the rapid development in the first 5–6 months most likely render it difficult to differentiate between the shape changes of the skull in wildcats prior to and after weaning. Such differences were noted in e.g. spotted hyenas, *Crocuta crocuta* (TANNER *et al.*, 2010). The authors argue for “protracted skull development, with adult morphology not achieved until well after reproductive maturity” (p. 359).

The sample of aged specimens with intact skulls available for this study was small, therefore, a larger sample should be aimed at in future. There were hardly any specimens older than 40 months (3 years) although the maximum possible age of wildcats was once estimated at up to 16 years (PIECHOCKI & MÖLLER, 1983), however currently it is assumed to be about 6 years (BÜTTNER, 1994). For the initial growth, the major growth spurt, and the shape changes the unavailability of aged specimens may not be problematic, but for the changes in the development of the nuchal and the sagittal crest as well as dtmpr it would be desirable to be able to follow them up to old age. Furthermore, using a larger sample and including the indicators of the lever arms of the masseter and the temporalis muscles according to RADINSKI (1981) might help to analyse the development of these muscles and their relative mechanical advantage as well as and the more detailed pre- and post-weaning differences in the skull development also for wildcats.

Aging of individuals

One aim of this study was to find linear measurements that could be used for the non-destructive age determination of skulls. Only a few variables were of po-

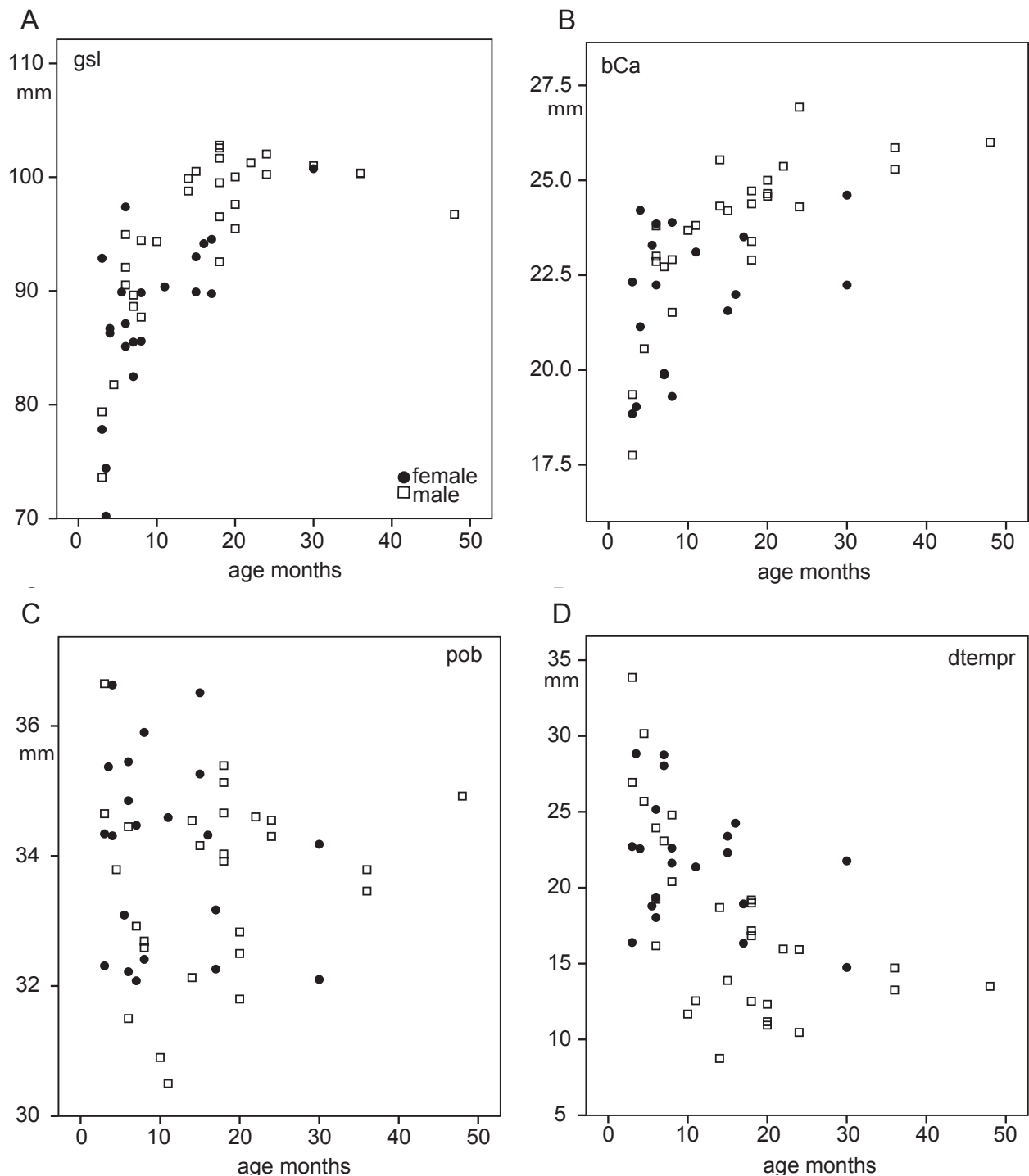


Fig. 6. Scatter diagrams of some cranial variables and age (in months) of the specimens separated according to sex. A) Greatest skull length (gsl), B) width across Canines (BCa), C) width of postorbital constriction (pob), D) distance between frontoparietal crests at their intersection with coronal suture (dtemp).

tential interest in this respect, particularly dtemp was considered as it was obvious to narrow with age when studying the skulls (also indicated in GARCIA-PEREA *et al.*, 1996). However, as in all variables, the strong overall variability (STEFEN & HEIDECHE, 2011) renders it unsuitable for the direct age-determination of specimens. Another possible measurement for age determination, nevertheless not considered here as other

published measurements for comparability were followed, would be the length of the developed sagittal crest. Given the overall variability for all the measurements taken, it can be assumed that the development and the size of the sagittal crest would also prove to be too variable for a good age determination.

Another non-destructive but also time-consuming method is the radiography of the mandible and the

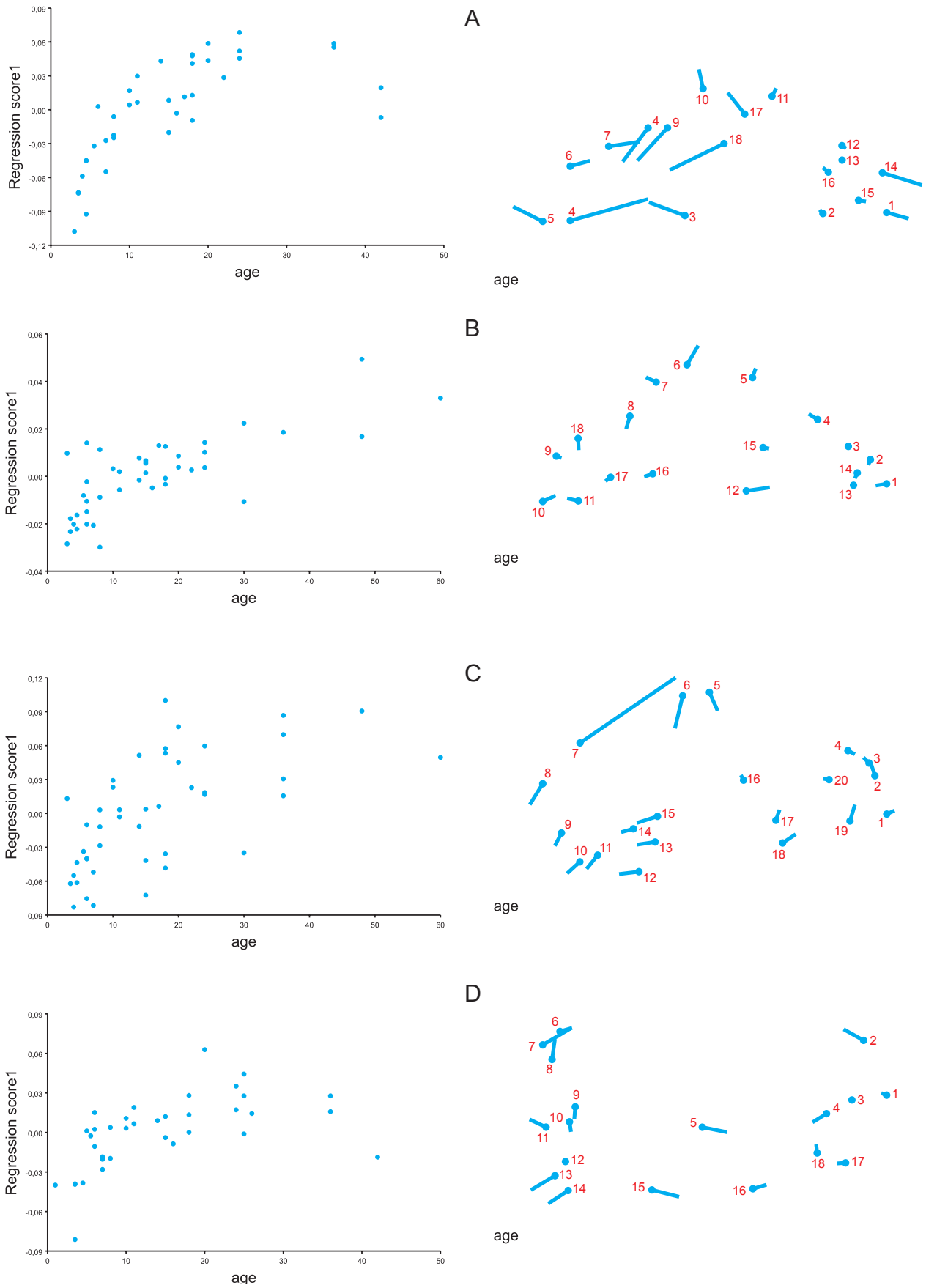


Fig. 7. Regressions of shape changes with age and illustrated shape change for wildcat skull and mandible. **A)** skull in dorsal view, **B)** skull in ventral aspect, **C)** skull in lateral aspect, and **D)** mandible. Size factor for all shape changes 100, only for lateral view 1000.

lower canine and the measurement of the pulp cavity opening. The older the specimen, the more filled is the pulp cavity (GUSTAVSON, 1950). BINDER *et al.* (2002) showed that this method yields similar results as the methodology of counting cementum annuli (e.g. KVAM 1984; PIECHOCKI & STIEFEL, 1988) which was used for lions and fossil saber-toothed cats (MEACHEN-SAMUELS & BINDER, 2010).

Acknowledgement

I would very much like to thank Mr. T. DATZMANN, Dresden, for taking most of the digital pictures, Dr. C. KLINGENBERG, Manchester, for his help with the geometric morphometrics analysis, and the reviewers for their helpful comments. Mrs. ORRISON, Dresden, checked the English.

References

- BEAUMONT, M., BARRAT, E.M., GOTTELLI, D., KITCHENER, A.C., DANIELS, M.J., PRITCHARDS, J.K. & BRUFORD, M.W. (2001): Genetic diversity and introgression in the Scottish wildcat. – *Molecular Ecology*, **10**: 319–336.
- BINDER, W.J., THOMPSON, W.N., & VAN VALKENBURGH, B. (2002): Temporal variation in tooth fracture among Rancho La Brea dire wolves. – *J. Vertebrate Paleontology*, **22**: 423–428.
- BÜTTNER, K. (1994): Katzenjammer vorbei? Bilanz des Wiederansiedlungsprojektes Wildkatze in Nordbayern. – *Nationalpark*, **85**(4): 17–21.
- CONDÉ, B. & P. SCHAUENBERG (1978): Remplacement des canines chez le Chat forestier *Felis silvestris* Schreb. – *Revue Suisse de Zoologie*, **85**(2): 241–244.
- DANIELS, M.J., BALHARRY, D., HIRST, D., KITCHENER, A.C. & ASPINALL, R.J. (1998): Morphological and pelage characteristics of wild living cats in Scotland: implications for defining the 'wildcat'. – *J. Zool. Lond.*, **244**: 231–247.
- DRAKE, A.G. & KLINGENBERG, C.P. (2008): The pace of morphological change: historical transformation of skull shape in St Bernard dogs. – *Proc. R. Soc. B*, **275**: 71–76.
- FERNÁNDEZ, E. & LOPE, F. de (1990): Sobre el dimorfismo sexual en el cráneo de gato montés *Felis silvestris* Schreber, 1777, en el suroeste ibérico. – *Donana, Acta Vertebrata*, **17**: 213–219.
- FRENCH, D.D., CORBETT, L.K. & EASTERBEE, N. (1988): Morphological discriminants of Scottish wildcats *Felis silvestris*, domestic cats *F. catus* and their hybrids. – *J. Zool. Soc. Lond.*, **214**: 235–259.
- GAUNT, W.A. (1959): The development of the deciduous cheek teeth of the cat. – *Acta Anat.*, **38**: 187–212.
- GARCÍA-PEREA, R. (1996): Patterns of Postnatal Development in Skulls of Lynxes, Genus *Lynx* (Mammalia: Carnivora). – *J. Morph.*, **229**: 241–254.
- GARCÍA-PEREA, R., BAQUERO, R.A., FERNÁNDEZ-SALVADOR, & GISEBERT, J. (1996): Desarrollo Juvenil de Craneo en las Poblaciones Ibericas de Gato Montes, *Felis silvestris* Schreber, 1777. – *Donana, Acta Vertebrata*, **23**(3): 153–164.
- GUSTAFSON, G. (1950): Age determinations on teeth. – *J. Am. Dent. Ass.* **41**: 45–54.
- KLINGENBERG, C.P. (2010): MorphoJ: an integrated software package for geometric morphometrics. – *Molecular Ecology Resources*, doi: 10.1111/j.1755-0998.2010.02924.x
- KRATOCHVÍL, J. & KRATOCHVÍL, Z. (1970): Die Unterscheidung von Individuen der Population *Felis s. silvestris* aus den Westkarpaten von *Felis s. f. catus*. – *Zool. Listy*, **19**(4): 293–302.
- KRATOCHVÍL, Z. (1973): Schädelkriterien der Wild- und Hauskatze (*Felis silvestris silvestris* Schreber 1777 und *Felis s. f. catus* L. 1758). – *Acta Sci. Nat. Brno*, **7**: 1–50.
- KRÜGER, M., HERTWIG, S.T., JETSCHKE, G. & FISCHER, M.S. (2009): Evaluation of anatomical characters and the question of hybridization with domestic cats in the wildcat population of Thuringia, Germany. – *J. Zool. Syst. Evol. Res.*, **47**: 268–282.
- KVAM, T. (1984): Age determination in European lynx *Lynx lynx* by incremental lines in canine tooth cementum. – *Acta Zool. Fenn.*, **171**: 221–223.
- MEACHEN-SAMUELS, J.A. & BINDER, W.J. (2010): Sexual dimorphism and ontogenetic growth in the American lion and sabertoothed cat from Rancho La Brea. – *J. Zool.*, **280**: 271–279.
- PIECHOCKI, R. (1990): Die Wildkatze *Felis silvestris*. – *Neue Brehm Bücherei A. Ziemsen Verlag, Wittenberg*, 232 S.
- PIECHOCKI, R. & MÖLLER, H. (1983): Über das Ansprechen, den Schutz und die Lebensweise der Wildkatze I, II, Schluß. – *Unsere Jagd*, **33**: 14–15, 52–53, 82–83.
- PIECHOCKI, R. & STIEFEL, A. (1988): Über die Altersstruktur der Verluste der Wildkatze (*Felis silvestris* Schreber 1777) – *Hercynia N. F.*, **25**: 235–258.
- RADINSKI, L.B. (1981): Evolution of skull shape in carnivores. I. Representative modern carnivores. – *Biol. J. Linn. Soc.*, **15**: 369–388.
- REIG, S., DANIELS, M.J. & MACDONALD, D.W. (2001): Craniometric differentiation within wild-living cats in Scotland using 3D morphometrics. – *J. Zool. Lond.*, **253**: 121–132.
- SCHAUENBERG, P. (1969): L'identification du Chat forestier d'Europe, *Felis s. silvestris* Schreber 1777, par une méthode ostéométrique. – *Rev. Suisse Zool.*, **76**: 433–441.
- SCHAUENBERG, P. (1977): Longueur de l'intestin du chat forestier *Felis silvestris* Schreber. – *Mammalia*, **41**(3): 357–30.
- SCHAUENBERG, P. (1980): Note sur le squelette et la maturité physique du chat forestier *Felis silvestris* Schreb. – *Revue Suisse Zool.*, **87**: 549–556.
- SLÁDEK, J., MOŠANSKÝ, A. & PALÁŠTHY, J. (1971): Die Variabilität der Schädelkapazität bei der Westkarpaten-Population der Wildkatze, *Felis silvestris* Schreber, 1777. – *Zool. Listy*, **20**(2): 153–160.

- SLÁDEK, J., MOŠANSKÝ, A. & PALÁŠTHY, J. (1972): Variabilität der linearen kranilogischen Merkmale bei der westkarpatischen Population der Wildkatze, *Felis silvestris* Schreber, 1777. – Zool. Listy, **21**(1): 23–37.
- SMITH, R.N. (1969): Fusion of Ossification Centres in the Cat. – J. Small Anim. Pract., **10**: 523–530.
- STEFEN, C. (2009): Intraspecific Variability of beaver teeth (Castoridae: Rodentia). – Zool. J. Linn. Soc., **155**: 926–936.
- STEFEN, C. & HEIDECHE, D. (2011): Kranio-metrische Variabilität der Wildkatze (*Felis silvestris* Schreber, 1777) im Harzgebiet. – Hercynia N. F., **44**: 253–285.
- STEFEN, C. & GÖRNER, M. (2009): Wildkatze in Deutschland und Mitteleuropa – zum Stand der Forschung und Konsequenzen für den Schutz. – Säugetierkd. Inf., **7**(38): 1–216.
- TANNER, J.B., ZELDITCH, M.L., LUNDRIGAN, B. L. & HOLEKAMP, K.E. (2010): Ontogenetic Change in Skull Morphology and Mechanical Advantage in the Spotted Hyena (*Crocuta crocuta*). – J. Morph., **271**: 353–365.
- TUMILSON, R. & MCDANIEL, R. (1984): Morphology, replacement mechanisms, and functional conservation in dental replacement patterns of the bobcat (*Felis rufus*). – J. Mamm., **65**: 111–117.
- YAMAGUCHI, N., DRISCOLL, C.A., KITCHENER A.C., WARD, J.M., & MACDONALD, D.W. (2004): Craniological differentiation between European wildcats (*Felis silvestris silvestris*), African wildcats (*F. s. lybica*) and Asian wildcats (*F. s. ornata*): implications for their evolution and conservation. – Biol. J. Linn. Soc., **83**: 47–63.